

# Ocular Involvement Following Postnatally Acquired *Toxoplasma gondii* Infection in Southern Brazil: A 28-Year Experience

TIAGO E.F. ARANTES, CLAUDIO SILVEIRA, GARY N. HOLLAND, CRISTINA MUCCIOLI, FEI YU, JEFFREY L. JONES, RAQUEL GOLDHARDT, KEVAN G. LEWIS, AND RUBENS BELFORT, JR

• **PURPOSE:** To determine the incidence of, and risk factors for, ocular involvement among people known to have postnatally acquired *Toxoplasma gondii* infection in a region of southern Brazil where there is a high prevalence of endemic disease.

• **DESIGN:** Retrospective longitudinal cohort study.

• **METHODS:** Records of 302 patients with serologic evidence of recent *T gondii* infection (a positive anti-*T gondii* IgM antibody test) from Erechim, Rio Grande do Sul state, Brazil (1974–2002) were analyzed. The incidence of ocular involvement was calculated in terms of person-years (PY) of follow-up. Risk factors for ocular involvement were analyzed using log-rank and Fisher exact tests.

• **RESULTS:** At initial ocular examination (baseline), 30 patients (9.9%) had intraocular inflammation only (anterior chamber cells and flare, vitreous inflammatory reactions, retinal whitening), without clinically apparent necrotizing retinochoroiditis. At baseline, men were more likely to have ocular involvement ( $P = .043$ ) and antiparasitic treatment was associated with less ocular involvement ( $P = .015$ ). Follow-up examinations were performed on 255 patients (median follow-up, 13.7 months [range 0.4–261.9 months]). Among those without ocular involvement at baseline, the incidence of necrotizing retinochoroiditis was 6.4/100 PY. Patients >40 years of age at first IgM test had a greater risk of incident necrotizing retinochoroiditis (hazard ratio = 4.47, 95% CI = 1.67–11.93,  $P = .003$ ) than younger patients. The incidence of recurrent necrotizing retinochoroiditis was 10.5/100 PY.

• **CONCLUSION:** Isolated intraocular inflammatory reactions can be an initial manifestation of *T gondii* infection, with necrotizing retinochoroiditis occurring months or

years later. Male sex and older age are risk factors for toxoplasmic retinochoroiditis. Antitoxoplasmic treatment may protect against early ocular involvement. (Am J Ophthalmol 2015;■:■–■. © 2015 by Elsevier Inc. All rights reserved.)

CURRENT EVIDENCE SUGGESTS THAT POSTNATALLY acquired *Toxoplasma gondii* infection is responsible for the majority of ocular toxoplasmosis cases.<sup>1–3</sup> Sources of infection include ingestion of tissue cysts in raw or undercooked meat and ingestion of oocysts in soil, water, or food contaminated with feces of infected cats.<sup>4–6</sup> The incidence and characteristics of ocular lesions related to recent postnatally acquired toxoplasmosis have been described during outbreaks,<sup>7–12</sup> but information about early ocular involvement, course of disease, and risk factors associated with ocular toxoplasmosis from sporadic, postnatally acquired *T gondii* infection is limited because of low prevalence in most regions and the fact that the time of initial *T gondii* infection typically is not known. Nonocular *T gondii* infection is often asymptomatic, and clinically apparent retinal lesions may first develop years after systemic infection; these factors preclude the determination of when most people with endemic ocular toxoplasmosis first became infected.<sup>1–4</sup>

In Erechim, a city located in an agricultural region of Rio Grande do Sul, the southernmost state of Brazil, up to 85% of the population is infected with *T gondii* and 17.7% of infected individuals have ophthalmic findings consistent with ocular toxoplasmosis.<sup>3</sup> In this study, we took advantage of the high prevalence of *T gondii* infection and associated ocular toxoplasmosis in Erechim to study the ophthalmic features of postnatally acquired *T gondii* infection.

## METHODS

IN THIS RETROSPECTIVE LONGITUDINAL COHORT STUDY, we used a dataset created by 1 author (C.S.) in 2002; it includes all patients older than 1 year of age, with at least 1 positive test for anti-*T gondii* IgM antibodies, who were examined between 1974 and 2002 by 1 ophthalmologist



Supplemental Material available at [AJO.com](http://ajoo.com).

Accepted for publication Feb 24, 2015.

From the Ocular Inflammatory Disease Center, Stein Eye Institute, and the Department of Ophthalmology, David Geffen School of Medicine at UCLA, Los Angeles, California (T.E.F.A., G.N.H., F.Y., R.G., K.G.L.); Clínica Silveira, Erechim, Rio Grande Do Sul, Brazil (C.S.); Department of Ophthalmology, Universidade Federal de São Paulo, São Paulo, Brazil (T.E.F.A., C.S., C.M., R.B.); and Division of Parasitic Diseases and Malaria, Center for Global Health, United States Centers for Disease Control and Prevention, Atlanta, Georgia (J.L.J.).

Inquiries to Gary N. Holland, Stein Eye Institute, 100 Stein Plaza, UCLA, Los Angeles, CA 90095-7000; e-mail: [uveitis@jsei.ucla.edu](mailto:uveitis@jsei.ucla.edu)

(author C.S.) at Clínica Silveira in Erechim, Rio Grande do Sul, Brazil. Patients either had been referred to Clínica Silveira because of a positive IgM antibody test ordered by a non-ophthalmologist for reasons other than eye disease, or had undergone IgM antibody testing as evaluation of presumed toxoplasmic retinochoroiditis without evidence of prior infection that was identified at Clínica Silveira. The specific reason that IgM testing was ordered for those patients referred to Clínica Silveira with positive tests was not recorded. A known reason for such testing is screening of women during pregnancy, especially for those who have lymphadenopathy and other constitutional signs and symptoms, because of high prevalence of *T gondii* infection in the general population. Individuals with positive anti-*T gondii* IgM tests are routinely referred by internists or obstetricians for ocular examination, whether or not they have visual symptoms, because of the high prevalence of ocular involvement among people with *T gondii* infection in that area. Not included in the dataset were individuals with acquired immunodeficiency syndrome (AIDS) or other immune system diseases and those receiving immunosuppressive drugs (other than corticosteroids for ocular toxoplasmosis). This study was approved by the Institutional Review Board (IRB) of the Universidade Federal de São Paulo (Comitê de Ética em Pesquisa da Universidade Federal de São Paulo–UNIFESP/EPM) prior to retrospective data collection, and analysis of previously collected, de-identified data was approved by the IRBs at the University of California, Los Angeles and the United States Centers for Disease Control and Prevention.

Anti-*T gondii* IgM antibody tests were performed at the Laboratório Fleury (São Paulo, Brazil), using either an indirect immunofluorescence assay or a microparticle enzyme immunoassay (Abbot AxSYM; Abbott Laboratories, Abbott Park, Illinois, USA). For the immunofluorescence assay, a titer  $\geq 1:16$  was considered positive. For the immunoenzymatic assay, values  $\leq 0.499$  were considered negative; values between 0.500 and 0.599 were considered indeterminate; and values  $\geq 0.600$  were considered positive. For the immunoenzymatic assay, the reported test sensitivity is 96.3% and specificity is 99.8% (package insert for Abbot AxSYM anti-*T gondii* IgM antibody assay), although sensitivity and specificity of the test has not been determined specifically for the population studied. The aforementioned values pertain to published test standards at the time of data collection. Although test kits may have changed with different cut-off values during the 28-year period of data collection, recording of positive results was always in reference to contemporary cut-off values.

• **DATA COLLECTION:** The following demographic and medical data were collected: age at time of first anti-*T gondii* IgM antibody test; age at first identification of ocular involvement related to *T gondii* infection (intraocular inflammatory reactions, necrotizing retinochoroiditis, retino-

choroidal scars); age at diagnosis of recurrent toxoplasmic retinochoroiditis; sex; presence of signs or symptoms of nonocular toxoplasmosis at time of IgM testing; and use of systemic anti-*T gondii* treatment at or before baseline. The following information was collected for each involved eye at each examination: presence or absence of intraocular inflammatory reactions (anterior chamber cells and flare, vitreous inflammatory reactions, retinal vascular sheathing, or focal retinal whitening without clinical evidence of retinal necrosis); presence or absence of necrotizing retinochoroiditis; and presence or absence of retinochoroidal scars. In a previous publication, the phenomenon of isolated focal retinal whitening in people with serologic evidence of recent *T gondii* infection has been shown to resolve without clinically apparent scar formation.<sup>13</sup> We have hypothesized that lesions represent foci of retinal infiltration where *T gondii* tissue cysts have colonized the retina.<sup>13</sup> In contrast to a study of epidemic disease,<sup>12</sup> retinal whitening was not categorized separately from other intraocular inflammatory reactions. For eyes with necrotizing retinochoroiditis, the size of the largest lesion ( $<1$  optic disc area [da] vs  $\geq 1$  da) and the presence or absence of macular and foveal involvement were determined. Data on intraocular pressure and visual acuity were not analyzed, as these were not relevant to the purpose of this study.

• **CONVENTIONS AND DEFINITIONS:** Baseline was defined as the date of the first eye examination that was performed either within 3 months before or at any time after the first positive anti-*T gondii* IgM antibody test. Ocular involvement that occurred within the window of 3 months before or 3 months after the first positive anti-*T gondii* IgM antibody test was considered to be “immediate” for purposes of the study. We used the same definitions of terms and study conventions that were used in our study of epidemic *T gondii* infection.<sup>12</sup> On the basis of these definitions, we categorized ophthalmic findings further using 1 or more of the following terms: necrotizing retinochoroiditis (denoting active disease); retinochoroidal scars consistent with healed *T gondii* retinal infection; isolated intraocular inflammatory reactions; initial necrotizing retinochoroiditis; recurrent necrotizing retinochoroiditis; primary lesions; satellite lesions; and first incident ocular disease.

• **DATA ANALYSIS AND STATISTICAL TECHNIQUES:** Incidence of ocular involvement was calculated in terms of events per 100 person-years (PY) of follow-up. For comparison of outcomes between those with and those without intraocular inflammatory reactions at baseline, Time 0 was defined as the baseline date. For other longitudinal analyses, Time 0 was defined as the date of first positive anti-*T gondii* IgM antibody test. Primary necrotizing retinochoroiditis lesions that occurred 6 months or longer after first positive anti-*T gondii* IgM antibody test were considered incident lesions, whether or not a prior eye examination had been performed. If primary necrotizing

**TABLE 1.** Demographic and Medical Data for 302 Individuals With Serologic Evidence of Postnatally Acquired *Toxoplasma gondii* Infection in Erechim, Brazil

Characteristics	Value
Sex, n (%)	
Male	129 (42.7%)
Female	173 (57.3%)
Age at baseline (y)	
Mean $\pm$ SD	21.9 $\pm$ 14.4
Median (range)	21 (1–63)
Clinically apparent nonocular toxoplasmosis at baseline, <sup>a</sup> n (%)	183 (68.3%) (total n = 268) <sup>b</sup>
Ophthalmic findings at baseline, n (%)	
Active disease	134 (44.4%)
Isolated intraocular inflammation <sup>c</sup>	30 (9.9%)
Initial, primary necrotizing retinochoroiditis	104 (34.4%)
Retinochoroidal scar only	5 (1.7%)
Antitoxoplasmic treatment at or before baseline, n (%)	159 (54.5%) (total n = 292) <sup>b</sup>
Follow-up data available after infection (n = 297), <sup>d</sup> n (%)	255 (85.9%)
Duration of follow-up after infection (mo)	
Mean $\pm$ SD	33.7 $\pm$ 49.8
Median (range)	13.7 (0.4–261.9)

SD = standard deviation.

<sup>a</sup>Arthralgia, fatigue, fever, malaise, lymphadenopathy, sore throat, or a combination of these disorders at the time of positive anti-*T gondii* IgM antibody testing.

<sup>b</sup>Number of individuals for whom values were known, if different than 302.

<sup>c</sup>Anterior chamber cells, retinal vitreous humor cells or haze, retinal vascular sheathing, retinal infiltrates without retinal necrosis, or a combination of these findings in the absence of necrotizing retinochoroiditis.

<sup>d</sup>Excluding those with scars at baseline (n = 5).

retinochoroiditis lesions were identified on a baseline examination that was performed between 3 and 6 months after the first positive anti-*T gondii* IgM antibody test, we felt that they could not be categorized reliably as being immediate or incident, and they were excluded from some analyses. For individuals with new retinochoroidal scars during follow-up, ocular disease was assumed to have occurred when the scar was identified, for purposes of calculating intervals.

Because only women were screened routinely for anti-*T gondii* IgM antibodies during pregnancy, there was the possibility of ascertainment bias, in which more women without disease were examined than men without disease. To address this issue and to investigate whether it was likely to influence relationships between sex or age and ocular disease, we compared men and women for the following factors: age at baseline; percent with ocular involvement at baseline; percent with systemic disease,

but no ocular involvement at baseline; and treatment at baseline. Because of the possibility that age at presentation could vary by indication for examination, we also compared the percent on treatment at baseline between younger ( $\leq 40$  years of age) and older ( $> 40$  years of age) patients.

Statistical analysis was performed using SAS software version 9.3 (SAS, Inc, Cary, North Carolina, USA). Cumulative risk of ocular involvement was estimated using the Kaplan-Meier method and compared using the log-rank test. Relative risks were expressed as hazard ratios (HR), estimated from Cox proportional hazards regression models. The Fisher exact test was performed to evaluate relationships between categorical variables, and the student *t* test was used in the analysis of continuous variables. A *P* value of  $< .05$  was considered to be statistically significant.

## RESULTS

A TOTAL OF 302 PATIENTS MET INCLUSION CRITERIA. AT baseline, 5 patients had inactive retinochoroidal scars, suggesting remote healed disease; these patients were excluded from analysis. The majority of patients (n = 239, 79.1%) had been referred for ocular evaluation because of a positive anti-*T gondii* IgM antibody test; for the other 63 patients (20.9%), the IgM test had been ordered by the examining ophthalmologist during investigation of initial primary necrotizing retinochoroiditis lesions. Ocular examination was performed within 3 months of, or at the same time as, the first positive anti-*T gondii* IgM antibody test in 258 patients (85.4%). Follow-up examinations after first positive anti-*T gondii* IgM antibody test were performed on 255 patients (median follow-up: 13.7 months [range 0.4–261.9 months]). During follow-up, persistence of anti-*T gondii* IgM antibodies for 1 year or longer on repeat testing was known to have occurred in 25 patients; they did not differ in demographic or clinical characteristics from the rest of the study population (data not shown).

Table 1 lists demographic, medical, and ophthalmic characteristics for the studied population. Isolated intraocular inflammation was present in 30 patients (9.9%) at baseline; inflammation was unilateral in 27 patients. In all but 2 patients, intraocular inflammation was observed within 3 months of the first positive IgM test (5 months in 1 case; 8 months in another). Women were more likely than men not to have clinically apparent systemic disease or ocular involvement at baseline (25.7% [38 of 148 patients] vs 5.0% [6 of 120 patients], respectively, *P*  $< .001$ ), as might be expected because of serologic screening during pregnancy. There were no significant differences, however, between men and women for the following factors at baseline: percent with ocular involvement; percent with systemic disease, but no ocular involvement; and treatment (Supplemental Table, available at [www.ajo.org](http://www.ajo.org)).

**TABLE 2.** Characteristics of Necrotizing Retinochoroiditis Lesions in Individuals With Serologic Evidence of Postnatally Acquired *Toxoplasma gondii* Infection in Erechim, Brazil

Lesion Characteristic	Necrotizing Retinochoroiditis		
	Immediate Lesions <sup>a</sup> (N = 97) <sup>d</sup>	Incident Primary Lesions <sup>b</sup> (N = 18) <sup>d</sup>	Recurrent Disease <sup>c</sup> (N = 31) <sup>d</sup>
Laterality, n (%) <sup>e</sup>			
Unilateral	87 (89.7%)	15 (83.3%)	30 (96.8%)
Bilateral	10 (10.3%)	3 (16.7%)	1 (3.2%)
Location in either eye, n (%) <sup>e</sup>		N = 15 <sup>f</sup>	
Extramacular only	49 (49.5%)	7 (46.7%)	15 (48.4%)
Macular	48 (50.5%)	8 (53.3%)	16 (51.6%)
Foveal involvement <sup>g</sup>	32 (68.1%)	NA	NA
Size of largest lesion, either eye, n (%) <sup>e</sup>	N = 95 <sup>f</sup>	N = 15 <sup>f</sup>	
≥1 DA	43 (45.3%)	4 (26.7%)	13 (41.9%)
<1 DA	52 (54.7%)	11 (73.3%)	18 (58.1%)
Number of lesions per eye, <sup>h</sup> n (%) <sup>e</sup>	N = 96 <sup>f</sup>	N = 15 <sup>f</sup>	N = 30 <sup>f</sup>
Unifocal	81 (84.8%)	13 (86.7%)	28 (93.3%)
Multifocal	15 (15.6%)	2 (13.3%)	2 (6.7%)

DA = disc area; NA = information not available.

<sup>a</sup>Primary necrotizing retinochoroiditis on initial eye examination, if the initial eye examination was prior to or at the same time of the first positive anti-*T gondii* IgM test (n = 87), or on initial eye examination performed within 3 months after the first positive anti-*T gondii* IgM antibody test (n = 10). Not considered as immediate lesions in this analysis were 7 of 104 initial primary necrotizing retinochoroiditis lesions at baseline examinations, for the following reasons. Patients with initial primary necrotizing retinochoroiditis lesions on baseline examinations performed 3–6 months after the first positive anti-*T gondii* IgM antibody test (n = 2) were excluded because these lesions could not be classified as either immediate or incident lesions. Patients with initial primary necrotizing retinochoroiditis lesions on baseline examinations performed more than 6 months after the first positive anti-*T gondii* IgM+ antibody test (n = 5) were considered incident lesions, as described in the text.

<sup>b</sup>Necrotizing retinochoroiditis on examination after the first positive anti-*T gondii* IgM antibody test, if additional, previous ophthalmic examinations had been performed since the first positive anti-*T gondii* IgM antibody test and revealed no evidence of retinochoroidal involvement (n = 13; 10 had no ocular involvement at baseline and 3 had intraocular inflammatory reactions at baseline); or an initial primary necrotizing retinochoroiditis lesion that was identified more than 6 months after the first positive anti-*T gondii* IgM antibody test (n = 5), whether or not there had been prior ophthalmic examinations.

<sup>c</sup>Recurrent disease was defined as necrotizing retinochoroiditis in the presence of old retinochoroidal scars in either eye. Data presented refers to the first recurrence.

<sup>d</sup>Number of individuals with necrotizing retinochoroiditis lesions.

<sup>e</sup>Number of individuals with characteristic among those with necrotizing retinochoroiditis in each column.

<sup>f</sup>Denominator, if less than all individuals with necrotizing retinochoroiditis for a given column.

<sup>g</sup>Among those with macular lesions; presence or absence of foveal involvement known for 47 of 48 macular lesions, among those with immediate necrotizing retinochoroiditis.

<sup>h</sup>Based on eye with largest number of lesions; 1 eye per patient.

com). With regard to age at baseline, men were slightly younger than women overall (mean,  $18.3 \pm 15.2$  years vs  $24.5 \pm 13.3$  years, respectively,  $P = .0002$ ), but the difference was unlikely to be clinically important in terms of disease characteristics. There was no significant difference between the proportion of men and women in the older age group at baseline (Supplemental Table, available at [www.ajoc.com](http://www.ajoc.com)). There was no significant difference between younger and older patients with respect to proportion treated at baseline (55.2% [144 of 261 patients] vs 48.4% [15 of 31 patients], respectively,  $P = .568$ ).

Table 2 lists the characteristics of retinal involvement at baseline and during follow-up. Lesions that developed during follow-up presented characteristics similar to those seen at baseline. Table 3 shows the comparison of selected

characteristics between patients with and those without ocular involvement at baseline. There were significantly more men than women with ocular involvement at baseline ( $P = .043$ ). The use of antitoxoplasmic medications before or at baseline was associated with less ocular involvement at initial examination ( $P = .015$ ); however, we could not confirm that such treatment prevented incident necrotizing retinochoroiditis lesions during follow-up (HR: 0.71, 95% confidence interval [CI] = 0.34–1.50,  $P = .37$ ).

Necrotizing retinochoroiditis after first positive IgM test developed in 29 individuals (either primary lesions at baseline or incident lesions during follow-up), with an incidence 10.0/100 PY. The cumulative risk of necrotizing retinochoroiditis at longest follow-up after *T gondii*

**TABLE 3.** Comparison of Selected Characteristics for Individuals With Serologic Evidence of Postnatally Acquired *Toxoplasma gondii* Infection in Erechim, Brazil With and Without Ocular Involvement at Baseline

	Immediate Eye Disease <sup>a</sup> (N = 125)	No Immediate Eye Disease (N = 169)	P Value <sup>b</sup>
Age at baseline (y)			.19 <sup>c</sup>
Mean $\pm$ SD	23.1 $\pm$ 15.1	20.9 $\pm$ 13.8	
Median (range)	22 (1–63)	19 (1–60)	
Age groups			.12
1–40 years	108 (86.4%)	156 (92.3%)	
>40 years	17 (13.6%)	13 (7.7%)	
Male sex, n (%) <sup>d</sup>	63 (50.4%)	64 (37.9%)	.043
Clinically apparent nonocular toxoplasmosis, <sup>e</sup> n (%) <sup>d</sup> (N = 261)	80 (70.8%) (n = 113) <sup>f</sup>	101 (68.2%) (n = 148) <sup>f</sup>	.69
Antitoxoplasmic treatment at baseline, n (%) <sup>d</sup>	53 (45.3%) (n = 117) <sup>f</sup>	101 (60.5%) (n = 167) <sup>f</sup>	.015
Follow-up data available, n (%) <sup>d</sup>	114 (91.2%)	122 (72.2%)	<.001
Follow-up (mo)			.40 <sup>g</sup>
Mean $\pm$ SD	42.9 $\pm$ 60.8	22.4 $\pm$ 30.4	
Median (range)	14.1 (0.6–261.9)	10.9 (0.5–157.8)	

SD = standard deviation.

<sup>a</sup>Primary necrotizing retinochoroiditis or isolated intraocular inflammation on initial eye examination, if the initial eye examination was within a 3-month window prior to or 3 months after the first positive anti-*T gondii* IgM antibody test (n = 97 necrotizing retinochoroiditis and 28 isolated intraocular inflammation).

<sup>b</sup>Fisher exact test, except when noted otherwise.

<sup>c</sup>Student *t* test.

<sup>d</sup>Number of individuals with characteristic among all individuals for each column.

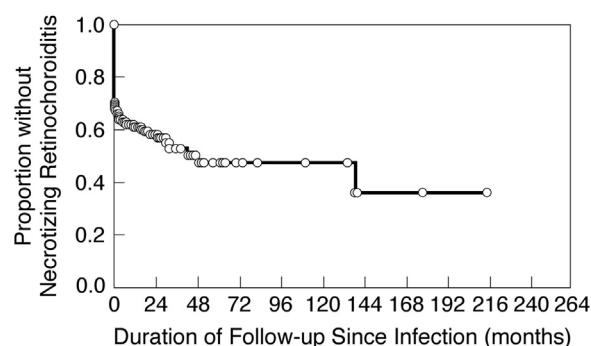
<sup>e</sup>Arthralgia, fatigue, fever, malaise, lymphadenopathy, sore throat, or a combination of these disorders at the time of positive anti-*T gondii* IgM antibody testing.

<sup>f</sup>Denominator if less than all individuals for each column.

<sup>g</sup>Kruskal-Wallis test.

infection for those at risk (214.9 months) was 64.5% (Figure 1), but the 95% CI was broad (43.9%–84.4%). Based on Kaplan-Meier analysis, the period of greatest risk for necrotizing retinochoroiditis was during the interval 0–48 months after *T gondii* infection; cumulative risk of necrotizing retinochoroiditis at the end of this interval was 49.9% (95% CI, 41.2%–59.3%). To allow comparison to a study of epidemic disease,<sup>12</sup> we also calculated the cumulative risk of necrotizing retinochoroiditis at 10.5 months after *T gondii* infection in this study (38.5%; 95% CI, 32.9%–44.7%).

The incidence of necrotizing retinochoroiditis after baseline for all individuals without such lesions at baseline was 6.8/100 PY. The incidence for those with isolated intraocular inflammation at baseline (9.0/100 PY; 3 patients with incident lesions) was not statistically different than the incidence for those without any previous ocular involvement (6.4/100 PY; 10 patients with incident lesions; HR = 1.63, 95% CI, 0.44–6.05, *P* = .46; Figure 2). The incidence of first recurrences among patients with necrotizing retinochoroiditis at baseline or during follow-up was 10.5/100 PY (Figure 3). Among 31 patients with recurrences, 19 (61%) had satellite lesions and 12 (39%) had primary recurrent lesions.



**FIGURE 1.** Kaplan-Meier plot showing the proportion of individuals with serologic evidence of postnatally acquired *T gondii* infection (anti-*T gondii* IgM antibodies) who remained free of necrotizing retinochoroiditis during follow-up. Time 0 corresponds to the first positive anti-*T gondii* IgM antibody test.

Patients without retinal lesions at the time of first positive IgM test who were older than 40 years were at higher risk of developing retinal lesions during follow-up than were younger age groups (HR = 4.47, 95% CI = 1.67–11.93, *P* = .003; Figure 4). Table 4 shows the comparison



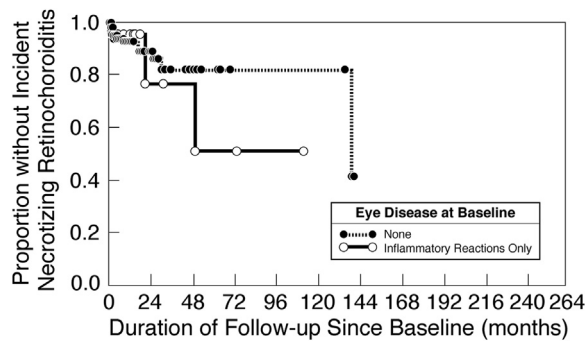


FIGURE 2. Kaplan-Meier plots showing the proportion of individuals with serologic evidence of postnatally acquired *T gondii* infection (anti-*T gondii* IgM antibodies) who remained free of necrotizing retinochoroiditis. No statistically significant difference was identified in risk of necrotizing retinochoroiditis between individuals with intraocular inflammation at initial eye examination (solid line) and those without (dotted line) intraocular inflammation at initial eye examination (hazard ratio = 1.63, 95% confidence interval = 0.44-6.05,  $P = 0.46$ ). Time 0 corresponds to the initial eye examination (baseline).

of selected host factors and retinal lesion characteristics. Older patients (>40 years) had larger retinal lesions ( $P = .044$ ), but no other associations were identified. In 3-way comparisons (ages 1–20 years; 21–40 years; >40 years), statistical differences were not identified when considering either risk for development of retinal lesions or the size of lesions; findings were similar for the 2 youngest age groups in each assessment (data not shown).

## DISCUSSION

STUDIES OF TOXOPLASMOSIS IN ERECHIM HAVE PROVIDED valuable information regarding the epidemiology, course, and characteristics of disease.<sup>3,5,13–17</sup> Approximately 85% of the population in this area has serologic evidence of *T gondii* infection, and the majority is thought to have been infected postnatally.<sup>3</sup> In support of this belief is the observation that <2% of cord blood specimens collected from hospitals in Erechim during 1990 contained anti-*T gondii* IgM antibodies, and more recent neonatal screening revealed the prevalence of *T gondii* infection to be only 1 per 3000 live births.<sup>18</sup> A population-based household survey in Erechim revealed that 17.7% of *T gondii*-infected individuals have retinochoroidal lesions consistent with ocular toxoplasmosis,<sup>3</sup> confirming a high prevalence of eye disease among individuals with postnatally acquired toxoplasmosis. The even higher cumulative risk of necrotizing retinochoroiditis in our study population (41.2% after 48 months) may be attributable to referral and ascertainment bias (with those having eye disease more likely to present for evaluation) or to differential loss to

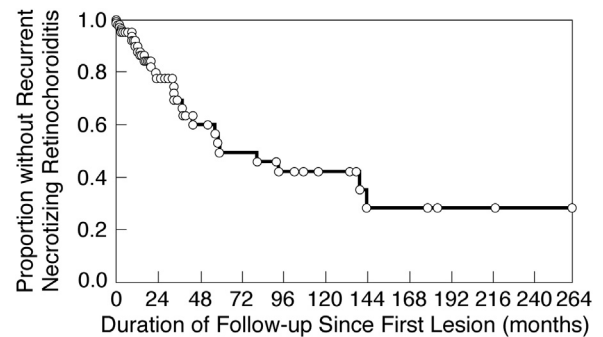


FIGURE 3. Kaplan-Meier plot showing the proportion of individuals with serologic evidence of postnatally acquired *T gondii* infection (anti-*T gondii* IgM antibodies) and necrotizing retinochoroiditis lesions who remained free of recurrences. Time 0 corresponds to the first identification of necrotizing retinochoroiditis.

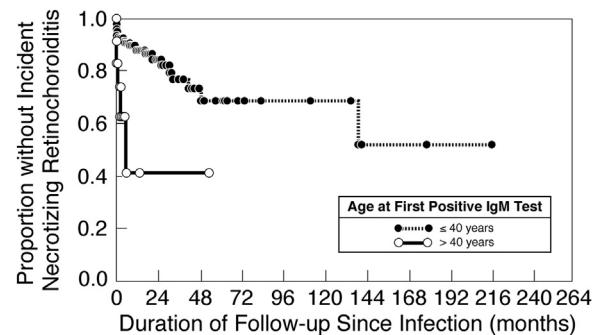


FIGURE 4. Kaplan-Meier plots showing the proportion of individuals with serologic evidence of postnatally acquired *T gondii* infection (anti-*T gondii* IgM antibodies) who remained free of necrotizing retinochoroiditis, grouped by age at first positive anti-*T gondii* IgM antibody test. There was a significantly increased risk of necrotizing retinochoroiditis among individuals older than 40 years (solid line; hazard ratio = 4.47, 95% confidence interval = 1.67–11.93,  $P = .003$ ) vs those 40 years of age or younger (dotted line). Time 0 corresponds to the first positive anti-*T gondii* IgM antibody test.

follow-up (with those having eye disease more likely to return for re-examination) or a combination of these factors. An artifactually high prevalence estimate will not necessarily influence the relationships between risk factors and timing or severity of disease, however.

The prevalence of *T gondii* infection and risk of ocular disease is substantially different in southern Brazil than in the United States, where only 14% of the general population is infected with *T gondii* by age 40 years,<sup>19</sup> and the prevalence of ocular toxoplasmosis among infected individuals has been estimated to be only 2%.<sup>2</sup> It has been hypothesized that these discrepancies are related to a difference in endemic parasite genotypes; there is a greater diversity of genotypes in southern Brazil than in North

**TABLE 4.** Comparison of Selected Host Factors and Retinal Lesion Characteristics for 302 Individuals With Serologic Evidence of Postnatally Acquired *Toxoplasma gondii* Infection in Erechim, Brazil

	Any Lesions	Bilateral Lesions	Macular Lesion (n = 114) <sup>a</sup>	Large Retinal Lesion (n = 112) <sup>b</sup>	Multifocal Lesion (n = 112) <sup>b</sup>
Individuals with lesion characteristic, n (%) <sup>c</sup>	117	14 (12.0%)	56 (49.1%)	48 (42.9%)	17 (15.0%)
Age at time of lesion					
1–40 years	96	11 (11.5%)	43 (46.2%)	35 (38.0%)	15 (16.1%)
>40 years	21	3 (14.3%)	13 (61.9%)	13 (65.0%)	2 (10.0%)
P value		.71	.23	.044	.73
Sex					
Male	59	7 (11.9%)	25 (44.6%)	22 (40.0%)	6 (10.7%)
Female	58	7 (12.1%)	31 (53.5%)	26 (45.6%)	11 (19.3%)
P value		1.00	.36	.57	.29
Clinically apparent nonocular toxoplasmosis <sup>d</sup> (n = 107) <sup>e</sup>					
Yes	77	12 (15.6%)	34 (46.0%)	30 (41.7%)	13 (17.8%)
No	30	2 (6.7%)	17 (56.7%)	15 (50.0%)	3 (10.0%)
P value		.34	.39	.51	.39
Antitoxoplasmic medication prior to or at baseline (n = 110) <sup>e</sup>					
Yes	48	7 (14.6%)	25 (54.4%)	22 (47.8%)	4 (8.7%)
No	62	7 (11.3%)	27 (44.3%)	24 (40.7%)	12 (20.0%)
P value		.77	.33	.55	.17
Interval from baseline to onset of ocular disease					
Immediate	104	12 (11.5%)	51 (49.0%)	45 (44.1%)	16 (15.5%)
Short (<1 year)	1	0	1 (100.0%)	0	0
Long (≥1 year)	12	2 (16.7%)	4 (44.4%)	3 (33.3%)	1 (11.1%)
P value		0.68	0.87	0.85	1.00

<sup>a</sup>Presence or absence of macular lesion known for 114 of 117 individuals.<sup>b</sup>Presence or absence of large lesions and of multifocal lesions known for 112 of 117 individuals.<sup>c</sup>Number of individuals with characteristic among those in each column for which characteristic known.<sup>d</sup>Arthralgia, fatigue, fever, malaise, lymphadenopathy, sore throat, or a combination of these disorders at the time of positive IgM testing.<sup>e</sup>Number for which host factor known if less than 117.

America and Europe, with a greater penetrance of parasites having atypical genotypes (known to be more virulent in animal models) into food animal stocks and the environment.<sup>20–22</sup> In support of this concept is the fact that in areas of the world where the risk of eye involvement is low, people with ocular toxoplasmosis are more likely to be infected with parasites having atypical genotypes than with the predominant, less virulent genotypes found in the general population.<sup>23–25</sup> Other influences could include the size of the inoculum, stage of the infecting parasite (oocysts from water and contaminated vegetables; tissue cysts from meat), and host factors. In other areas of Brazil, the prevalence of *T gondii* infection is lower than in Erechim and ocular lesions have been seen in only 3.4%–10.8% of infected individuals.<sup>26,27</sup>

We previously reported the presence of isolated intraocular inflammatory reactions among recently infected individuals, in a selected case series.<sup>13</sup> With this study, we can assign a prevalence to these reactions (approximately 10%); however, as the signs are transient, the true

prevalence may be even higher. We have hypothesized that the reactions are a response to the presence of *T gondii* in retinal tissue.<sup>13</sup> In support of this hypothesis is the observation that patients have been observed eventually to develop typical necrotizing retinochoroiditis lesions in the same areas that transient retinal whitening had occurred, suggesting that lesions arose from occult tissue cysts that remained in the retina since the time of the original infection.<sup>13</sup> It is likely that, in the presence of an intense protective host immune response generated by the initial systemic infection, there is an insufficient amount of parasite activity to cause clinically apparent retinal necrosis at the time of infection. The nature of the reactions may be related to the genotype of the infecting parasite and its unique interaction with the host immune system; thus, it may vary in prevalence and severity between populations, but the phenomenon has been seen in other areas of the world as well.<sup>13</sup> We could not confirm that the presence of isolated inflammatory reactions was associated with a higher risk for development of incident

necrotizing retinochoroiditis, as was observed among people infected in an epidemic of *T gondii* infection,<sup>12</sup> possibly because of methodologic differences between studies. In contrast to this study, during investigation of the epidemic, retinal whitening was recorded separately from other signs of intraocular inflammation and studied as an independent risk factor. Also, these transient reactions are also more likely to be missed among sporadic examinations of people with endemic disease than among individuals followed in a systematic manner following a point-source outbreak. Differential loss to follow-up between symptomatic and nonsymptomatic cases is more likely to have occurred among the people with endemic disease in Erechim, who were not part of a public health investigation, as with the epidemic; this problem would dilute the differences between study subgroups.

Our study confirms previous observations that ocular disease can occur years after initial, systemic *T gondii* infection.<sup>2,15</sup> A former study in Erechim revealed that, during a 7-year period, 8.3% of seropositive individuals without previous retinal lesions developed typical toxoplasmic retinochoroidal lesions,<sup>15</sup> corresponding to a calculated incidence of approximately 1.2/100 PY, which is substantially lower than the calculated incidence for this study (10.0/100 PY). This discrepancy may be explained not only by referral bias, but by the fact that risk of ocular disease appears to decrease with increasing interval after an active episode of retinochoroiditis.<sup>28</sup> Nevertheless, our calculated incidence can serve as a standardized benchmark against which future studies of early ocular involvement in different populations can be compared.<sup>29</sup>

The incidence of necrotizing retinochoroiditis was higher among patients older than 40 years, consistent with a previous longitudinal cohort study from the Netherlands, in which patients older than 40 years of age were at a higher risk of recurrences,<sup>28</sup> and providing additional support for the hypothesis that age is a risk factor for ocular disease.<sup>28,30</sup> Also consistent with previous studies,<sup>30–33</sup> patients older than 40 years in our study had larger retinal lesions. Furthermore, the relationships are biologically plausible; earlier and larger lesions may reflect a reduced ability to limit replication of parasites, because of waning immune function with aging.<sup>30–32</sup> The fact that we did not see an effect of age among subgroups younger than 40 years may reflect a threshold effect, in which age influences disease only among older patients.

Ocular disease at baseline was more frequent in men ( $P = .043$ ), consistent with other studies showing that men are at greater risk of ocular toxoplasmosis, possibly because of occupational exposures.<sup>5</sup> We found no evidence to suggest that the relationship was the result of referral biases. Because there are so many potential influences on ocular disease, it is not surprising that statistical associations are weak in the absence of extensive controls.

*T gondii* infection is usually asymptomatic among immunocompetent patients in the United States and Europe,

where only approximately 10% of individuals develop a nonspecific and self-limited lymphadenopathic illness.<sup>4</sup> In contrast, 68.3% of the study patients had systemic signs or symptoms that could be attributed to toxoplasmosis, consistent with a previous study from Brazil, in which 64.8% of patients with recent *T gondii* infection had systemic signs and symptoms of disease.<sup>27</sup> This high prevalence of clinically apparent disease may reflect the more virulent genotypes found in southern Brazil. Conversely, it could also reflect referral bias. Nevertheless, this bias should not influence the observed associations between risk factors and ocular disease.

Traditionally, many individuals with systemic toxoplasmosis are not treated, because of its self-limited nature. In our study, the proportion of individuals with ocular involvement at baseline was smaller among those who had taken antiparasitic medication than among those who were untreated. This observation might reflect a reduction in the number of circulating parasites during the early stages of infection in treated individuals, with fewer organisms gaining access to retinal tissue across vascular walls. Children with congenital toxoplasmosis who are treated with antiparasitic medication during the first year of life have a reduced risk of ocular toxoplasmosis during follow-up, when compared to historic studies of untreated children.<sup>34</sup> Treatment during follow-up was not recorded; we were therefore unable to assess whether treatment at baseline alone provided a similar long-lasting protection against ocular disease. The potential for protection against ocular involvement warrants reconsideration of initial treatment for recently infected individuals and an assessment of its long-term effects. Identification of infected individuals will be difficult if they remain asymptomatic, but 1 suggested target population for screening and treatment is family members and other close contacts of people known to have recent *T gondii* infection, because of the likelihood of similar exposures.<sup>35</sup> Macular lesions were frequent, both at baseline and during follow-up. Bosch-Driessen and associates have emphasized the fact that patients with ocular toxoplasmosis are at risk for late vision loss from such lesions,<sup>36</sup> which highlights the importance of long-term follow-up and the potential benefit of preventing development of early lesions altogether.

Several epidemics of *T gondii* infection have been notable for the large number of infected people with ocular involvement, even in geographic areas where prevalence of ocular toxoplasmosis is otherwise low.<sup>7,8</sup> It has been suggested that the high prevalence of ocular involvement during outbreaks of *T gondii* infection might be attributed to larger inocula or to the stage of the parasite (oocysts in waterborne outbreaks).<sup>2,10</sup> Study of a 2001 outbreak in Santa Isabel do Ivaí, Brazil allowed us to make some comparisons between endemic disease, as seen in this study, and epidemic disease in a similar setting with examinations performed by the same ophthalmologist (C.S.), during overlapping time frames. The 2 studies



show that risk for, and early course of, ocular involvement can be similar between endemic and epidemic *T gondii* infections. During the Santa Isabel do Ivaí epidemic, 11.5% of infected individuals had ocular involvement at initial examination. In the current study, 34.4% of patients already had necrotizing retinochoroiditis at baseline examination, but this discrepancy may relate to differences in study design; the interval between infection and baseline examination was, in general, longer in the current study. Cumulative risk of necrotizing retinochoroiditis at 10.5 months after *T gondii* infection in this study (38.5%; 95% CI, 32.9%–44.7%) was similar to that for the Santa Isabel do Ivaí epidemic (30.1% at 10.5 months after onset of the epidemic; 95% CI, 14.0%–57.1%). The strain of *T gondii* responsible for the Santa Isabel do Ivaí epidemic was highly atypical,<sup>37</sup> but the genotype was not the same as any found among atypical strains identified in the Erechim region.<sup>21</sup> Thus, similarities between findings in the 2 studies probably reflect the fact that strains of *T gondii* in Brazil are, in general, highly virulent, but findings are not strictly genotype-specific.

These studies do not support the hypothesis that the stage of the infecting parasite influences disease severity or course. The Santa Isabel do Ivaí epidemic was traced to a cistern contaminated by cat feces; thus, all infections were caused by ingestion of oocysts. In contrast, a previous study in Erechim found that endemic disease is caused by ingestion of either oocysts or tissue cysts.<sup>5</sup> The studies show that, in general, endemic disease and epidemic disease follow similar early courses, at least in similar settings. Specific differences between studies may reflect design issues, including different durations of follow-up. Endemic disease cases in Erechim were not followed in a systematic manner, as was done after the Santa Isabel do Ivaí epidemic.

Strengths of our study include the large sample size, a long duration of follow-up for many individuals, and

examinations by a single observer. High event rates in this population made it possible to identify associations that might not be obvious elsewhere in the world. Limitations of this study include its retrospective nature and the differential duration of patient follow-up. Referral bias may have affected prevalence of findings at baseline, and thus, those values were not emphasized in our analyses; less likely to have been affected were incidence of new ocular disease during follow-up and risk factor analyses. We cannot rule out the possibility that referral bias resulted in additional confounding factors not considered in our subgroup comparisons. Although presence of anti-*T gondii* IgM antibodies is commonly accepted as evidence of recent infection, it is imprecise. These antibodies can persist for a year or longer after initial infection and are occasionally seen during recurrent disease.<sup>38–41</sup> Unfortunately, more refined methods for identifying recent infections are not routinely available. The fact that the majority of study patients had symptomatic systemic disease supports the assumption that they had recently acquired infection.

In summary, our study supports the association between endemic, postnatally acquired *T gondii* infection and ocular toxoplasmosis. It shows that necrotizing retinochoroiditis can develop as long as 12 years after infection and may continue to reactivate over years. Our study has also helped to refine our understanding of early events in the course of ocular toxoplasmosis. It supports previous observations that isolated intraocular inflammatory reactions may be an initial ophthalmic manifestation of *T gondii* infection, and provides further support for the notions that male sex and old age are risk factors for earlier and more severe ocular toxoplasmosis. Antitoxoplasmic treatment at the time of systemic infection may protect against ocular involvement; however, additional study is needed to determine whether prevention of early ocular disease has an additional long-term protective effect against later development of ocular lesions. Future studies will need to employ more sensitive and specific determinants of recent infection.

---

ALL AUTHORS HAVE COMPLETED AND SUBMITTED THE ICMJE FORM FOR DISCLOSURE OF POTENTIAL CONFLICTS OF INTEREST. Dr Holland has served on Advisory Boards for the following companies: Genentech, Incorporated (San Francisco, California, USA); Novartis International AG (Basel, Switzerland); Santen, Incorporated (Emeryville, California, USA); and Xoma (US) LLC (Berkeley, California, USA). Dr Belfort has served on Advisory Boards or has received grants from Alcon/Novartis International AG (Basel, Switzerland), Allergan, Incorporated (Irvine, California, USA), Bayer AG (Leverkusen, Germany), Kemin Industries (Des Moines, Iowa, USA), NovaBay Pharmaceuticals, Incorporated (Emeryville, California, USA), and Santen, Incorporated (Emeryville, California, USA). Funding: Supported by the Conselho Nacional de Desenvolvimento Científico e Tecnológico and the Fundação de Amparo à Pesquisa do Estado de São Paulo (CNPq/FAPESP), São Paulo, Brazil (Drs Silveira, Muccioli, Belfort); Research to Prevent Blindness (RPB), Inc, New York, New York (Dr Holland), the Skirball Foundation, New York, New York (Dr Holland), and the Centers for Disease Control and Prevention (Dr Jones). Dr Holland is recipient of an RPB Physician-Scientist Award. Funding entities had no role in the reporting of study data and the interpretation of the data. Contribution of authors: study design (C.S., G.N.H., F.Y., J.L.J., K.G.L.); data collection (C.S.); data management and analysis (T.E.F.A., C.S., G.N.H., F.Y., R.G.); data interpretation (T.E.F.A., C.S., G.N.H., C.M., F.Y., J.L.J., R.G., K.G.L., R.B.); preparation of initial draft of manuscript (T.E.F.A., G.N.H., F.Y.); review and approval of manuscript (T.E.F.A., C.S., G.N.H., C.M., F.Y., J.L.J., R.G., K.G.L., R.B.).

---

## REFERENCES

1. Gilbert RE, Stanford MR. Is ocular toxoplasmosis caused by prenatal or postnatal infection? *Br J Ophthalmol* 2000;84(2): 224–226.
2. Holland GN. Ocular toxoplasmosis: a global reassessment. Part I: epidemiology and course of disease. *Am J Ophthalmol* 2003;136(6):973–988.
3. Glasner PD, Silveira C, Kruszon-Moran D, et al. An unusually high prevalence of ocular toxoplasmosis in southern Brazil. *Am J Ophthalmol* 1992;114(2):136–144.
4. Montoya JG, Liesenfeld O. Toxoplasmosis. *Lancet* 2004; 363(9425):1965–1976.
5. Jones JL, Muccioli C, Belfort R Jr, Holland GN, Roberts JM, Silveira C. Recently acquired *Toxoplasma gondii* infection. Brazil. *Emerg Infect Dis* 2006;12(4):582–587.
6. Jones JL, Dargelas V, Roberts J, Press C, Remington JS, Montoya JG. Risk factors for *Toxoplasma gondii* infection in the United States. *Clin Infect Dis* 2009;49(6):878–884.
7. Bowie WR, King AS, Werker DH, et al. Outbreak of toxoplasmosis associated with municipal drinking water. The BC Toxoplasma Investigation Team. *Lancet* 1997; 350(9072):173–177.
8. Burnett AJ, Shortt SG, Isaac-Renton J, King A, Werker D, Bowie WR. Multiple cases of acquired toxoplasmosis retinitis presenting in an outbreak. *Ophthalmology* 1998;105(6): 1032–1037.
9. Balasundaram MB, Andavar R, Palaniswamy M, Venkatapathy N. Outbreak of acquired ocular toxoplasmosis involving 248 patients. *Arch Ophthalmol* 2010;128(1):28–32.
10. Holland GN. An epidemic of toxoplasmosis: lessons from Coimbatore, India. *Arch Ophthalmol* 2010;128(1):126–128.
11. de Moura L, Bahia-Oliveira LM, Wada MY, et al. Waterborne toxoplasmosis, Brazil, from field to gene. *Emerg Infect Dis* 2006;12(2):326–329.
12. Silveira C, Muccioli C, Holland GN, et al. Ocular involvement following an epidemic of *Toxoplasma gondii* infection in Santa Isabel do Ivaí, Brazil. *Am J Ophthalmol*. (forthcoming).
13. Holland GN, Muccioli C, Silveira C, Weisz JM, Belfort R Jr, O'Connor GR. Intraocular inflammatory reactions without focal necrotizing retinochoroiditis in patients with acquired systemic toxoplasmosis. *Am J Ophthalmol* 1999;128(4): 413–420.
14. Silveira C, Belfort R Jr, Burnier M Jr, Nussenblatt R. Acquired toxoplasmic infection as the cause of toxoplasmic retinochoroiditis in families. *Am J Ophthalmol* 1988;106(3): 362–364.
15. Silveira C, Belfort R Jr, Muccioli C, et al. A follow-up study of *Toxoplasma gondii* infection in southern Brazil. *Am J Ophthalmol* 2001;131(3):351–354.
16. Silveira C, Belfort R Jr, Muccioli C, et al. The effect of long-term intermittent trimethoprim/sulfamethoxazole treatment on recurrences of toxoplasmic retinochoroiditis. *Am J Ophthalmol* 2002;134(1):41–46.
17. Silveira C, Vallochi AL, Rodrigues da Silva U, et al. *Toxoplasma gondii* in the peripheral blood of patients with acute and chronic toxoplasmosis. *Br J Ophthalmol* 2011;95(3):396–400.
18. Silveira C. Determinação da Forma de Toxoplasmose Ocular: Congênita ou Adquirida. In: Silveira C, ed. *Toxoplasmose: Dúvidas e Controvérsias*. 1st ed. Erechim: EdiFAPES; 2002:53–55.
19. Jones JL, Kruszon-Moran D, Sanders-Lewis K, Wilson M. *Toxoplasma gondii* infection in the United States, 1999–2004, decline from the prior decade. *Am J Trop Med Hyg* 2007;77(3):405–410.
20. Dubey JP, Navarro IT, Sreekumar C, et al. *Toxoplasma gondii* infections in cats from Parana, Brazil: seroprevalence, tissue distribution, and biologic and genetic characterization of isolates. *J Parasitol* 2004;90(4):721–726.
21. Khan A, Jordan C, Muccioli C, et al. Genetic divergence of *Toxoplasma gondii* strains associated with ocular toxoplasmosis, Brazil. *Emerg Infect Dis* 2006;12(6):942–949.
22. Shwab EK, Zhu XQ, Majumdar D, et al. Geographical patterns of *Toxoplasma gondii* genetic diversity revealed by multilocus PCR-RFLP genotyping. *Parasitology* 2014;141(4):453–461.
23. Grigg ME, Ganatra J, Boothroyd JC, Margolis TP. Unusual abundance of atypical strains associated with human ocular toxoplasmosis. *J Infect Dis* 2001;184(5):633–639.
24. Shobab L, Pleyer U, Johnsen J, et al. *Toxoplasma* serotype is associated with development of ocular toxoplasmosis. *J Infect Dis* 2013;208(9):1520–1528.
25. McLeod R, Boyer KM, Lee D, et al. Prematurity and severity are associated with *Toxoplasma gondii* alleles (NCCCTS, 1981–2009). *Clin Infect Dis* 2012;54(11):1595–1605.
26. Neves ES, Bicudo LN, Curi AL, et al. Acute acquired toxoplasmosis: clinical-laboratorial aspects and ophthalmologic evaluation in a cohort of immunocompetent patients. *Mem Inst Oswaldo Cruz* 2009;104(2):393–396.
27. Silva CS, Neves Ede S, Benchimol EI, Moraes DR. Postnatal acquired toxoplasmosis patients in an infectious diseases reference center. *Braz J Infect Dis* 2008;12(5):438–441.
28. Holland GN, Crespi CM, ten Dam-van Loon N, et al. Analysis of recurrence patterns associated with toxoplasmic retinochoroiditis. *Am J Ophthalmol* 2008;145(6):1007–1013.
29. Jabs DA. Improving the reporting of clinical case series. *Am J Ophthalmol* 2005;139(5):900–905.
30. Holland GN. Ocular toxoplasmosis: the influence of patient age. *Mem Inst Oswaldo Cruz* 2009;104(2):351–357.
31. Johnson MW, Greven GM, Jaffe GJ, Sudhakar H, Vine AK. Atypical, severe toxoplasmic retinochoroiditis in elderly patients. *Ophthalmology* 1997;104(1):48–57.
32. Labalette P, Delhaes L, Margaron F, Fortier B, Rouland JF. Ocular toxoplasmosis after the fifth decade. *Am J Ophthalmol* 2002;133(4):506–515.
33. Dodds EM, Holland GN, Stanford MR, et al. Intraocular inflammation associated with ocular toxoplasmosis: relationships at initial examination. *Am J Ophthalmol* 2008;146(6): 856–865.e852.
34. Phan L, Kasza K, Jalbrzikowski J, et al. Longitudinal study of new eye lesions in treated congenital toxoplasmosis. *Ophthalmology* 2008;115(3):553–559.e558.
35. Jones JL, Bonetti V, Holland GN, et al. Ocular toxoplasmosis in the United States: recent and remote infections. *Clin Infect Dis* 2015;60(2):271–273.
36. Bosch-Driessen LE, Berendschot TT, Ongkosuwito JV, Rothova A. Ocular toxoplasmosis: clinical features and prognosis of 154 patients. *Ophthalmology* 2002;109(5):869–878.
37. Vaudaux JD, Muccioli C, James ER, et al. Identification of an atypical strain of *Toxoplasma gondii* as the cause of a

- waterborne outbreak of toxoplasmosis in Santa Isabel do Ivaí, Brazil. *J Infect Dis* 2010;202(8):1226–1233.
38. Welch PC, Masur H, Jones TC, Remington JS. Serologic diagnosis of acute lymphadenopathic toxoplasmosis. *J Infect Dis* 1980;142(2):256–264.
  39. Del Bono V, Canessa A, Bruzzi P, Fiorelli MA, Terragna A. Significance of specific immunoglobulin M in the chronological diagnosis of 38 cases of toxoplasmic lymphadenopathy. *J Clin Microbiol* 1989;27(9):2133–2135.
  40. Gomez-Marin JE, Montoya-De-Londono MT, Castano-Osorio JC, et al. Frequency of specific anti-Toxoplasma gondii IgM, IgA and IgE in Colombian patients with acute and chronic ocular toxoplasmosis. *Mem Inst Oswaldo Cruz* 2000;95(1):89–94.
  41. Gras L, Gilbert RE, Wallon M, Peyron F, Cortina-Borja M. Duration of the IgM response in women acquiring Toxoplasma gondii during pregnancy: implications for clinical practice and cross-sectional incidence studies. *Epidemiol Infect* 2004;132(3):541–548.



### **Biosketch**

Dr Tiago E. F. Arantes is Chief of the Uveitis Service at Altino Ventura Foundation, Recife, Brazil. Dr Arantes completed a Medical Retina Fellowship at the University of São Paulo, a Clinical Uveitis Fellowship at the Federal University of São Paulo, and an International Fellowship in Uveitis and Inflammatory Eye Diseases in the Department of Ophthalmology, David Geffen School of Medicine at UCLA and the Stein Eye Institute. His research interests involve inflammatory diseases of the eye and imaging techniques for retinal diseases.

**SUPPLEMENTAL TABLE.** Comparison of Selected Factors at Baseline Between Men and Women with Serologic Evidence of Postnatally Acquired *Toxoplasma gondii* Infection in Erechim, Brazil

Factor	Men	Women	P Value <sup>a</sup>
Percent in older age group (>40 years of age)	10.1% (13/129 patients)	10.4% (18/173 patients)	1.00
Percent with ocular involvement	51.2% (66/129 patients)	42.2% (73/173 patients)	.131
Percent with systemic disease, but no ocular involvement	43.3% (52/120 patients)	31.8% (47/148 patients)	.057
Percent treated prior to or at baseline	59.7% (74/124 patients)	50.1% (85/168 patients)	.154

<sup>a</sup>Fisher exact test.